

Left ventricular thrombus formation in a patient with normal ejection fraction

Dr. Nihan Kahya Eren, Dr. Sadık Volkan Emren, Dr. Hamza Duygu, Dr. Uğur Kocabaş

Cardiology Clinic, Atatürk Training and Research Hospital, İzmir

Summary– Left ventricular (LV) thrombi usually occur in the presence of impaired LV function, such as in dilated cardiomyopathy, aneurysm or following myocardial infarction. Thrombus formation in a normally functioning LV is extremely rare. We report a patient with LV thrombus formation despite a normal systolic function. The patient, who was admitted to the emergency service with transient loss of consciousness and diagnosed with cerebral embolism, was found to have a pedunculated and hypermobile mass in the LV apex by echocardiography. The LV mass was excised by urgent surgery due to its high embolic risk. The histopathological examination revealed that the LV mass was a thrombus. This case highlights that although very rare, LV thrombus formation may occur in patients with normal ejection fraction.

Özet– Sol ventrikülde (LV) trombüs oluşumu genellikle dilate kardiyomyopati, anevrizma veya miyokart enfarktüsü sonrasında olduğu gibi LV fonksiyonunun bozulmuş olduğu durumlarda gerçekleşmektedir. Normal fonksiyonlu LV’de trombüs oluşumu ise oldukça nadirdir. Olgumuz sistolik fonksiyonu normal olmasına rağmen LV’inde trombüs saptanan bir hastadır. Geçici bilinç kaybı şikâyeti ile acil servise başvuran ve serebral emboli düşünülen olguda, ekokardiyografi ile LV apeksinde saplı ve ileri derecede hareketli kitle saptandı. Emboli riskinin yüksek olması nedeniyle kitle acil olarak cerrahi yolla çıkarıldı. Histopatolojik incelemede LV’deki kitlenin trombüs olduğu saptandı. Bu olgu çok nadir de olsa normal ejeksiyon fraksiyonlu olgularda da LV’de trombüs gelişebileceğini göstermesi açısından önemlidir.

Submitted on : 11.10. 2012 Accepted for publication on: 03.26. 2013

Address of correspondence: Dr. Nihan Kahya Eren. 166 Sokak, No 8/3, Basinsitesi, Konak, İzmir.

Phone: +90 266 - 244 44 44 / 2552 e-mail: nkahya77@yahoo.com

Abbreviations:

EF Ejection fraction

ECG Electrocardiography

LV Left ventricle

Formation of thrombus in the left ventricle is generally seen in cases with ventricular systolic dysfunction. Very rarely, formation of left ventricular (LV) thrombi has been reported in the individuals with normal ejection fraction. Echocardiography is a sensitive, and specific imaging modality for the identification of LV thrombi.. In our case echocardiographic evaluation was performed with the indication of cerebral embolism, and a mobile LV thrombus was detected in the patient with normal systolic function.

CASE REPORT

A 45-year-old female patient consulted to a hospital with transient loss of consciousness lasting for 15 minutes. After recovery of her consciousness, ataxic gait was detected which necessitated referral to our hospital with an initial diagnosis of ischemic cerebrovascular event. Upon detection of early stage lacunar infarcts in both cerebral hemispheres on diffusion magnetic resonance images obtained in

our hospital, cardiologic evaluation was performed to investigate the origin of cardiac embolism. On physical examination, cardiac, and respiratory sounds were physiologic, and peripheral pulses were patent. Her electrocardiographic (EKG) pattern was of sinus rhythm (Figure 1). On transthoracic echocardiogram, left ventricular ejection fraction (LVEF) was 67 %, and a pedunculated, hypermobile intraventricular mass on the apical region of the inferior wall was detected. For more detailed evaluation of the thrombotic mass, transesophageal echocardiograms was obtained which visualized a pedunculated, heterogenous, hypermobile mass (1.8 x 0.8 cm) located on the apical region of the LV. (Video 1*) The mass was predominantly thought to be a myxoma, and then thrombus with the least probability. Risk of systemic embolism was presumably higher in this patient with a history of cerebral embolism which led us to perform emergency surgical excision. Histopathological analysis of the mass was consistent with thrombus (Figure 2) without any evidence of tumor cells. Levels of thrombophilic factors, protein C, protein S, antithrombin 3, lupus anticoagulant, and ANA which might lead to a state of hypercoagulability were within normal limits.

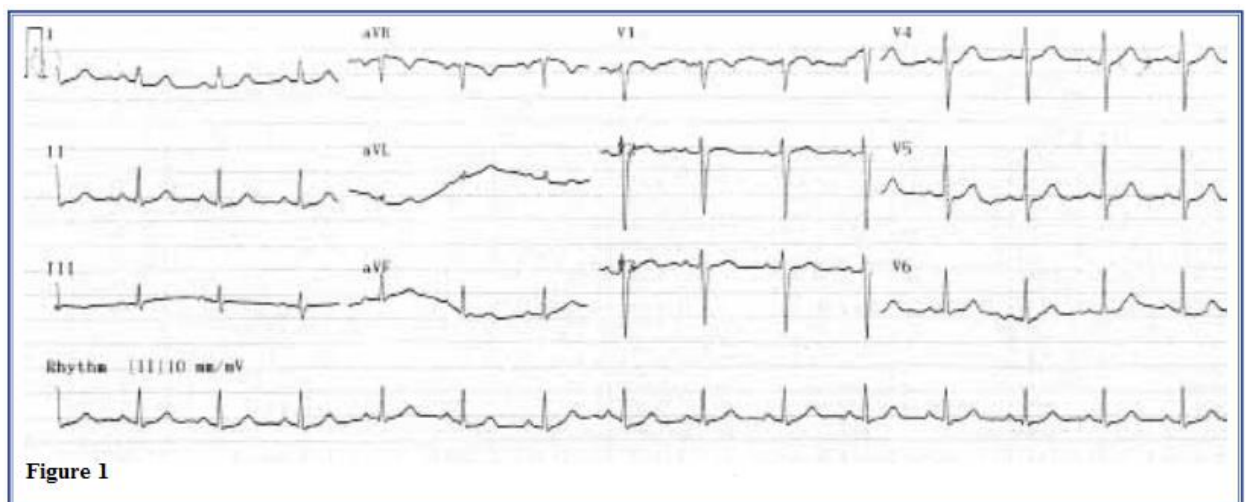

Figure 1

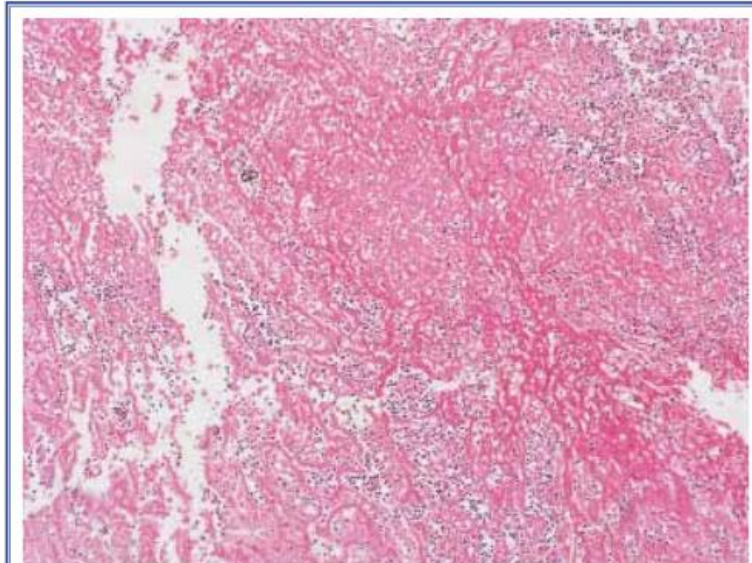


Figure 2

DISCUSSION

Echocardiography is a very valuable imaging modality in the evaluation of intracardiac masses, and specification of their location, shape, and mobility.[1] In the differential diagnosis of LV masses, thrombi, primary or metastatic cardiac tumors, congenital remnants, and hypertrophic muscle bundles should not be forgotten [1,2]. Myxoma is the most frequently seen primary tumor of the heart in adults, and in less than 5% of the cases it is located in the left ventricle[3]. Myxomas are typically pedunculated, mobile masses with heterogenous density. In our case, intraventricular location of the pedunculated, hypermobile, heterogenous mass in a patient with completely normal LV systolic function priorly suggested the presence of a myxoma. However, histopathologic examination disclosed a thrombotic mass.

Thrombus formation in the left ventricle is known to occur generally in ~~eases~~ with the presence of LV systolic dysfunction such as dilated cardiomyopathy, aneurysm formation or following a myocardial infarction[4]. Left ventricular thrombus formation in individuals with normal EF is a rarely seen phenomenon. Very rarely, thrombus formation in a normal

functioning LV has been reported in the presence of primary [5,6] or secondary [2,7] abnormalities predisposing to thrombosis such as protein C, protein S deficiency, antiphospholipid syndrome, malignant or myeloproliferative diseases. In addition, it has been already recognized that in cases with idiopathic hypereosinophilic syndrome, toxic eosinophilic granules directly traumatize endocardium possibly leading to the formation of thrombus, and peripheral embolism[8]. Chin et al.[9] reported a case with LV thrombus associated with inflammatory bowel disease, and cocaine use. It has been suggested that predisposition to thrombosis secondary to inflammatory bowel disease was enhanced by platelet aggregation promoting effects of cocaine. Wiyono et al.[10] reported formation of a LV thrombus in a case with pheochromocytoma. In pheochromocytoma, it was asserted that during adrenergic discharges, myocardial ischemia due to supply-demand mismatch might lead to transient LV dysfunction, increased aggregation of platelets ensuing in the formation of thrombus. In cases with Takotsubo cardiomyopathy which leads to reversible LV dysfunction following intense physical or emotional stress, rarely formation of

a LV thrombus can be seen. In these cases, thrombus has been generally observed during the periods of LV systolic dysfunction.[11] Sasaki et al.[12] reported formation of LV thrombus with resultant renal artery embolization after normalization of LV function in a patient followed up with the diagnosis of Takotsubo cardiomyopathy.

In the evaluation of clinical features, and laboratory results of our case, we couldn't detect any evidence suggestive of any abnormality. As is seen in our case, formation of LV thrombus in healthy individuals with normal EF, but without any abnormality predisposing to formation of thrombi is relatively rare[2]. In these patients hypothesis of microvascular ischemia has been proposed as a triggering mechanism for the aggregation of platelets by means of inducing patchy areas of endocardial fibrosis, and formation of thrombi on these endomyocardial areas[2]. ECG of our patient was unremarkable, and she didn't describe any episode of chest pain. The patient was emergently operated, so we didn't have time to perform preprocedural coronary angiography. During resection of the thrombotic mass, endomyocardial biopsy might be helpful in the clarification of the culprit pathophysiology in these patients. Again, evaluation of these patients with cardiac MRI might be helpful both in the differential diagnosis of the mass lesion, and in the elucidation of the causative pathophysiologic mechanisms.

Most of the patients reported in the literature with LV thrombi and a normal EF consist of cases with systemic embolism [2,5-7,10]. Sivasankaran et al. [13] incidentally detected LV thrombi in two cases without any antecedent embolism. Even though they reported complete resolution of the thrombotic mass with anticoagulant therapy, in these patients, it seems appropriate to remove the thrombotic mass surgically on an emergency basis because of increased risk of systemic embolism, and the need for finalization of the diagnosis, before initiation of oral anticoagulant therapy.

Formation of LV thrombi can occur very rarely in individuals with normal LV systolic function. Echocardiographic examination should be meticulously performed even in patients with normal EF who had suffered from systemic embolism so as to detect the presence of mass lesion or thrombus formation in the ventricle.

*Video file is available in the internet address of this article

Conflict of interest: None declared

REFERENCES

1. Peters PJ, Reinhardt S. The echocardiographic evaluation of intracardiac masses: a review. *J Am Soc Echocardiogr* 2006;19:230-40.
2. Verma AK, Alam M, Rosman HS, Brymer J, Keith F. Systemic embolization from thrombus in normal left ventricles. *Chest* 1988;93:441-2.
3. Keeling IM, Oberwalder P, Anelli-Monti M, Schuchlenz H, Demel U, Tilz GP, et al. Cardiac myxomas: 24 years of experience in 49 patients. *Eur J Cardiothorac Surg* 2002;22:971-7.
4. Haugland JM, Asinger RW, Mikell FL, Elsperger J, Hodges M. Embolic potential of left ventricular thrombi detected by two-dimensional echocardiography. *Circulation* 1984;70:588-98.
5. Matitiau A, Tabachnik E, Sthoeger D, Birk E. Thrombus in the left ventricle of a child with systemic emboli: an unusual presentation of hereditary protein C deficiency. *Pediatrics* 2001;107:421-2.
6. Kawamoto J, Ishibashi K, Shibukawa T, Izutani H. Left ventricular thrombus with a normal heart. *Gen Thorac Cardiovasc Surg* 2007;55:322-4.
7. Allende NG, Sokn F, Borracci R, Milani A, Kusselevski A, Camilletti J, et al. Giant pedunculated thrombus with normal left ventricular systolic function mimicking myxoma. *Echocardiography* 2011;28:E31-3.
8. Gottdiener JS, Maron BJ, Schooley RT, Harley JB, Roberts WC, Fauci AS. Two-dimensional echocardiographic assessment of the idiopathic hypereosinophilic syndrome. Anatomic basis of mitral regurgitation and peripheral embolization. *Circulation* 1983;67:572-8.
9. Chin WW, Van Tosh A, Hecht SR, Berger M. Left ventricular thrombus with normal left

ventricular function in ulcerative colitis. *Am Heart J* 1988;116:562-3.

10. Wiyono SA, Vletter WB, Soliman OI, ten Cate FJ, Geleijnse ML. Thrombus in a normal left ventricle: a cardiac manifestation of pheochromocytoma. *Echocardiography* 2010;27:195-7.

11. de Gregorio C, Grimaldi P, Lentini C. Left ventricular thrombus formation and cardioembolic complications in patients with Takotsubo-like syndrome: a systematic review. *Int J Cardiol* 2008;131:18-24.

12. Sasaki N, Kinugawa T, Yamawaki M, Furuse Y, Shimoyama M, Ogino K, et al. Transient left ventricular apical ballooning in a patient with

bicuspid aortic valve created a left ventricular thrombus leading to acute renal infarction. *Circ J* 2004;68:1081-3.

13. Sivasankaran S, Harikrishnan S, Tharakan JM. Left ventricular thrombi in the presence of normal left ventricular function. *Indian Heart J* 2002;54:196-8.

Key words: Adult; thrombosis/etiology; thrombosis/ultrasonography; ventricular dysfunction, left.

Anahtar sözcükler: Erişkin; tromboz/etioloji/ultrasonografi; ventrikül işlev bozukluğu, sol.